Practical Instructions on Non-Facial IPL Skin Treatments Using Photorejuvenation with IPL™ Quantum SR

MAURICE A. ADATTO, M.D.,

Medical Director, Skinpulse Dermatology & Laser Center, Geneva, Switzerland

INTRODUCTION. Photoaging of the skin as a result of aging and overexposure to the sun is a common concern which is manifested particularly on the face. This problem has been addressed by ablative means, such as topical and chemical agents, dermabrasion and lasers, but these methods have prolonged healing times and a high risk of adverse effects[1]. During the past three years, there has been an increasing demand among patients for skin rejuvenation, due to the no-downtime aspect of the procedure and the minimal complications involved.

IPL Skin Treatments using Photorejuvenation is becoming a technique used by many physicians to improve the appearance of their patients' facial skin[2-5]. This modality involves a non-invasive, non-ablative intense pulsed light (IPL) technology which simultaneously treats epidermal and dermal pigmented and vascular lesions, as well as improving skin appearance. The procedure consists of targeting some of the symptoms of aging skin: dilated blood vessels[6], mottled pigmentation[7,8] and structural changes[9]. Some physicians using this IPL modality have reported structural changes in correlation with new collagen synthesis[2,10], and its rearrangement in an orderly fibrillar pattern[11]. The destruction of benign superficial dilated or broken capillaries, and excessive melanin containing cells, as well as the activation of fibroblasts cytokine secretion and the resultant stimulation of collagen, elastin, and glycosaminoglycans, yield a simultaneous improvement in skin color and general appearance. The smoother appearance of the skin may be also due to sebaceous glands shrinkage[12]. Among the skin conditions that improve with IPL technology are red and brown discoloration, including telangiectasia, erythema, rosacea, melasma, age spots, mottled pigmentation, poikiloderma of Civatte, and scars.

Many patients, upon seeing the overall improved appearances of their treated faces, want to match it with non-facial exposed areas. Thus, there are increasing requests to treat the neck, chest, arms and the dorsum of the hands.

At our clinic, we began to see significant improvement in non-facial areas when, realizing that the skin in these areas is more fragile and sensitive than facial skin, we began to treat these areas with a different set of clinical parameters. The sensitivity of non-facial skin is due to its thinner nature and to the lower density of sebaceous glands in these areas than on the face, resulting in slower re-epithelization. Ablative lasers, such as CO_2 and chemical peels, as well as any type of physical external aggression (dermabrasion, etc.) are not well tolerated by non-facial areas. Treatment with such modalities may result in an increased risk of complications, such as crusting, blistering, hyperpigmentation, hypopigmentation or scarring in non-facial areas. With IPL Skin Treatments using Photorejuvenation, these types of complications on non-facial areas are rare if care is taken to use the appropriate treatment parameters. Thus, this non-ablative technique is the only acceptable modality for non-facial areas with virtually no downtime and minimal risk of adverse effects.

The objective of this article is to describe the successful outcome of performing IPL Skin Treatments using Photorejuvention on over 1,000 patients since September 1999, with special reference to non-facial areas, using the IPL™ Quantum SR (produced by Lumenis Ltd).

MATERIALS AND METHODS

IPL™ QUANTUM SR SYSTEM

The IPL Quantum SR system consists of an IPL source, which operates with a broad wavelength spectrum ranging from 500 to 1200nm. The 560nm cut-off filter is used in treating patients with Fitzpatrick Skin Type I to III. For treating patients with a darker skin type (IV and V), a 590nm as well as a 640nm cut-off filter are available. The 590 and 640nm cut-off filters are used in all skin types when deeper penetration of the light is desired, such as in treating 0.5-1 mm depth vascular/pigmented lesions and scars, respectively. The fluence range is 15 to 45 J/cm^2 and can be divided into 2 or 3 pulses due to the Multiple Synchronised Pulsing feature. The spot size of the treatment head measures 8 x 34 mm and is cooled by a thermo-electric cooler in Off, Medium or Max states. When treating non-facial areas, maximum chilling was always selected, in order to provide added protection to these sensitive areas. The non-facial areas normally do not possess very superficial vascular lesions (unlike the face) and therefore vasoconstriction as a reaction to maximum chilling is unlikely to occur.

TREATMENT PROCEDURE

Before treatment, all make-up and skin creams were removed with a gentle non-alcoholic cleanser, avoiding irritation of the skin. The area to be treated was divided into quadrants. Concentrating on one quadrant at a time, a thick layer (2-3 mm) of cold transparent gel (directly from the refrigerator) was applied immediately prior to the treatment. Depending on skin type and the non-facial area to be treated, appropriate parameters were selected (see Table 1 or the Case Discussions). More than one pass could be performed occasionally in treating facial areas with lighter skin, depending on the patient's tolerance and the indications. However, a second pass is not recommended on non-facial areas with any skin type.

Following 1 or 2 pulses with the selected parameters on a treatment zone, a waiting period of 2-3 minutes for light skin is required to determine the effect on the skin. Darker skin may need a longer waiting period. By allowing 5-10% overlapping, we avoided leaving untreated gaps. Bearing in mind that non-facial areas are more fragile than the face, a less intense erythema than on the face is acceptable on non-facial areas. The end point is usually a very slight erythema which appears gradually.

In our clinic, the treatment head is always used parallel to the skin's surface, in direct contact with the gel, without touching the skin. Nevertheless, in some clinics, satisfactory treatment protocol includes a light contact with the skin, but with a reduction in fluence of 1-3 J/cm^2. When treating a very convex or concave area, we add enough extra gel to ensure direct contact between the light guide and the gel in these uneven parts.

Treatment was performed without any type of anesthesia (local or topical), as the procedure causes minimal pain and discomfort. The patient feels the flash emitted as a little hot snap, like a mild sunburn. This sensation may be felt by the patient for a couple of hours after the treatment.

RESULTS AND DISCUSSION

PARAMETERS

For the first session, when treating non-facial areas, we typically lowered the fluence that is normally used on the face. Reducing the fluence by 1-2 J/cm^2 when treating the neck and another 1-2 J/cm^2 when treating the chest or forearms/hands yielded satisfactory results, e.g., 28 J/cm^2 on the face, 26-27 J/cm^2 on the neck and 24-25 J/cm^2 on the chest and forearms or hands. In addition, we found it advantageous to use a milder Pulse Type Program on non-facial areas than on the face. For example, skin type I on non-facial areas would be treated with the milder Program 2, whereas the same skin type on facial areas would be treated with Program 1. Likewise, when treating skin type III on non-facial areas, the second pulse width would be increased to 7.0 msec from 5.0 msec on the face. Treating a darker skin type III, the pulse duration and delay may be further increased. Only one pass was applied and overlap was 5-10%.

Skin types I to III were best treated with the 560nm cut-off filter; skin type IV required either 590 or 640nm cut-off filters. In treating skin type V for non-facial IPL Skin Treatments, it is advised to use caution. Use only the 640nm cut-off filter, do test spots, and wait 24-48 hours to observe the response. Guidelines for treatment parameters for skin types I to III are shown in Table 1. If too much erythema appears soon after the test patch, the fluence should be lowered by 2 J/cm^2, the delay between the pulses may be increased by 5-15 ms, and another test should be performed.

Non-Facial Area	Skin Type I (J/cm^2 - Program)	Skin Type II (J/cm^2 - Program)	Skin Type III (J/cm^2 - Program)
Neck	24-28 J/cm^2 Program 2	24-28 J/cm^2 Program 3	24-27 J/cm^2 Program 3 modified. Second pulse width = 7.0 msec
Chest	23-25 J/cm^2 Program 2	23-25 J/cm^2 Program 3	23-25 J/cm^2 Program 3 modified. Second pulse width = 7.0 msec
Forearms/Hands	23-25 J/cm^2 Program 2	23-25 J/cm^2 Program 3	23-25 J/cm^2 Program 3 modified. Second pulse width = 7.0 msec

Table 1. Suggested settings for treating non-facial areas of different skin types with the 560nm filter

Program 2 designates a pulse type of double sub-pulses: 2.4 and 5 ms, with a delay of 15 ms between pulses.

Program 3 designates a pulse type of double sub-pulses: 2.4 and 6 ms, with a delay of 15 ms between pulses.

CASES DISCUSSIONS

Representative cases of neck, chest, forearms and hands treatments using the IPL™ Quantum SR show a marked improvement in the vascular, pigmented and structural lesions. As sessions progress, treatment parameters are slightly more aggressive with higher fluences but a milder pulse type. Four to five sessions using 23-28 J/cm^2 with a mild pulse type of program 2-3 yielded excellent result with no downtime and no side effects. Two sessions gave satisfactory results, but the treatments are on-going.

CASE 1

A 49 year old female patient, Fitzpatrick skin type II, with poikiloderma on her neck. She received a total of 5 sessions of IPL Skin Treatments using Photorejuvenation. The "brightness" shown corresponds to the smoothing effect of the skin, there is an overall, global improvement in her skin aspect, and no side effects were noted. The clinical parameters used are as follows:

- **1st session:** cut-off filter 560nm, 26 J/cm^2, modified program 3 (2.4/15/7.0).
- **2nd session:** cut-off filter 560nm, 27 J/cm^2, modified program 3 .
- **3rd session:** cut-off filter 560nm, 27 J/cm^2, program 3 (2.4/15/6.0).
- **4th session:** cut-off filter 560nm, 27 J/cm^2, program 3.
- **5th session:** cut-off filter 560nm, 28 J/cm^2, program 3.

There is marked improvement in skin color and a marked smoothing effect, with no side effects.

CASE 2

A 51 year old female patient, Fitzpatrick skin type III, presented with telangiectasia and pigmentation on her chest. Following a series of 4 IPL Skin Treatments using Photorejuvenation at one month intervals, the skin showed a dramatic improvement in vascular and pigmented lesions and no side effects were noted.

Case 1. Left: A 49 year old woman with poikiloderma on her neck, before treatment. Right: Five months after the last treatment (5 sessions). Note the global improvement in skin aspect.

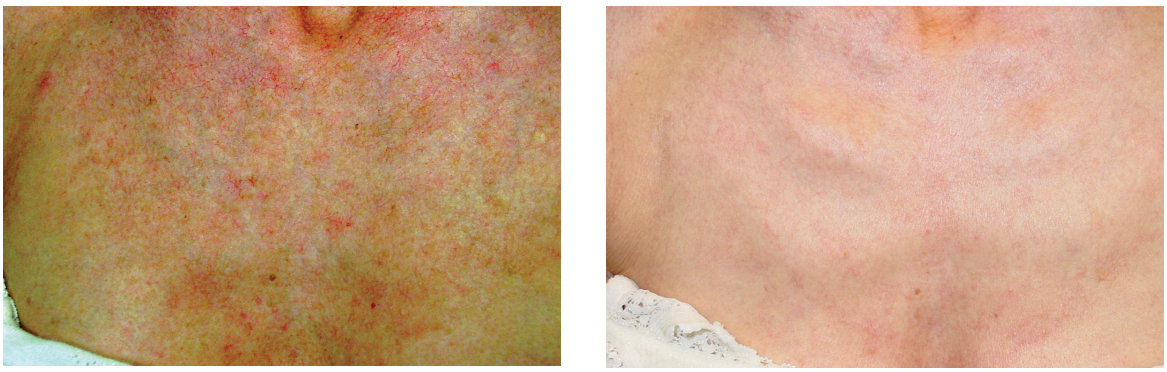

Case 2. Left: A 51 year old woman with telangiectasia and pigmentation on her chest. Right: One month following the last treatment (4 sessions), there is a dramatic improvement in vascular and pigmented lesions.

- **1st session:** cut-off filter 560nm, 26 J/cm², modified program 3 (2.4/15/7.0).
- **2nd session:** cut-off filter 560nm, 26 J/cm², program 3 (2.4/15/6.0).
- **3rd session:** cut-off filter 560nm, 27 J/cm², modified program 3.
- 4**th session:** cut-off filter 560nm, 27 J/cm², program 3.

CASE 3

A 58 year old female patient, Fitzpatrick skin type dark III, presented with pigmentation on her forearms and hands. Following a series of 2 IPL Skin Treatments using Photorejuvenation at 5 weeks interval, the skin showed an improvement and no side effects were noted. Treatment is on-going.

- **1st session:** cut-off filter 560nm, 24 J/cm², modified program 3 (3.0/20/6.0).
- **2nd session:** cut-off filter 560nm, 25 J/cm², modified program 3 (3.0/20/6.0).

Case 3A. Left: A 58 year old woman with pigmentation on her forearm. Right: One month following the last treatment (2 sessions) the skin shows an improvement in the pigmented lesions.

Case 3B. Left: A 58 year old woman with lentigines on her hands. Right: One month following the last treatment (2 sessions), the skin shows a dramatic improvement in the pigmented lesions.

AFTER TREATMENT CARE

Following treatment, the area was cooled down by ice packs for a few minutes and some soothing cream, such as Aloe Vera was applied. Patients were advised to avoid sun exposure and to use a complete sun block (at least SPF 30). Otherwise, they could resume all their normal activities.

CONCLUSION

Photoaged skin on sun exposed body areas may present a variety of lesions which are not acceptable cosmetically. They include pigmented and vascular lesions, their combination appearing as poikiloderma, and structural changes. IPL Skin Treatments using Photorejuvenation with the IPL™ Quantum SR, which is non-invasive and non-ablative, has provided good facial results with no downtime and no adverse effects, unlike the conventional ablative modalities.

Treatment of the non-facial areas of neck, chest, hands and arms, which are more sensitive areas than the face, calls for an even milder approach. This was achieved by using the same technique, with milder treatment parameters than on the face. The simultaneous care of photoaged non-facial vascular, pigmented and structural changes has been shown in this study. IPL, as a broadband light source, targets epidermal and junctional melanin as well as hemoglobin in the dermal vessels. The improved skin texture could be attributed to collagen remodelling, by which the collagen bundles may be targeted through a direct absorption in collagen[10], and/or indirectly by heat conduction and by response to fibroblasts secreted cytokines. Sebaceous glands shrinkage may also contribute to the tighter skin look[12]. The overall result on non-facial areas, after a series of 4 to 5 treatments, consists of skin that looks significantly more uniform in color and even in texture, in agreement with Weiss et al[13]. The ability to treat the non-facial areas as well as facial areas creates a better overall homogenous appearance of these sun exposed skin areas.

REFERENCES

1. Goldman MP, Fitzpatrick RE, Smith SS. Resurfacing complications and their management in: Coleman WP, Lawrence N ed. Laser resurfacing. 1997. Williams & Williams, Baltimore.
2. Bitter PH. Noninvasive rejuvenation of photodamaged skin using serial, full face Intense Pulsed Light treatments. Dermatol Surg. 2000;26:835-43.
3. Goldberg DJ. New collagen formation after dermal remodelling with an Intense Pulsed Light source J Cutan Laser Ther. 2000;2:59-61.
4. Weiss RA, Goldman MP, Weiss MA. Treatment of poikilodermia of Civatte with an Intense Pulse Light source. Dermatol Surg. 2000;26:823-8.
5. Negishi K, Tezuka Y, Kushikata N, Wakamatsu S. Photorejuvenation for Asian skin by Intense Pulsed Light. Dermatol Surg 2001;27:627-32.
6. Angermeier MC. Treatment of facial vascular lesions with Intense Pulsed Light. J Cutan Laser Ther. 1999; 1:95-100.
7. Moreno Arias G, Ferrando J. Intense Pulsed Light for melanocytic lesions. Dermatol Surg. 2001;27:397-400.
8. Adatto MA. Photorejuvenation of the forearms by treating hyperpigmented lesions with Intense Pulsed Light source: a case report. J Cosmetic & Laser Ther 2003;5:117-9.
9. Goldberg DJ, Samady JA. Intense Pulsed Light and Nd:YAG laser non-ablative treatment of facial rhytids. Lasers Surg Med. 2001;28:141-4.
10. Negishi K, Wakamatsu S, Kushikata N, Tezuka Y, Kotani Y, Kyouko S. Full-face photorejuvenation of photodamaged skin by Intense Pulsed Light with integrated contact cooling: initial experience in Asian patients. Lasers Surg Med. 2002; 30:298-305.
11. Hernandez-Perez E, Ibiett EV. Gross and microscopic findings in patients submitted to nonablative full-face resurfacing using Intense Pulsed Light: a preliminary study. Dermatol Surg 2002; 28:651-655.
12. Sadick NS. IPL hailed as new nonablative technology generation. Cosmetic Surg. Times 2002; 5 (6).
13. Weiss RA, Weiss MA, Beasley KL. Rejuvenation of photoaged skin: 5 years results with intense pulsed light on the face and chest. Dermatol Surg. 2002; 28:1115-9.

Lumenis, Inc.
2400 Condensa Street
Santa Clara, CA 95051
USA
Tel. +1.408.764.3000
Tel. 800.635.1313
Fax. +1.408.764.3999

Lumenis (Holland) BV
P.O.B. 8185
1180 LD Amstelveen
The Netherlands
Tel. +31.20.347.5060
Fax. +31.20.347.5099

Lumenis Japan Co. Ltd.
2nd Floor, No. 31, Kowa Bldg.
19-1 Shirokanedai, 3-Chome
Minato-ku, Tokyo 108-0071
Japan
Tel. +81.3.5789.8300
Fax. +81.3.5789.8310

PB3680360